

Expression of Proliferating Cell Nuclear Antigen (PCNA) in Oral Submucous Fibrosis: An Immunohistochemical Study

ROOPAVATHI KESHAV¹, UMASHREE NARAYANAPPA²

ABSTRACT

Background and objectives: Expression of Proliferating Cell Nuclear Antigen (PCNA) well-correlates with the cell division. The suprabasal expression of PCNA is considered to be a marker of dysplastic oral mucosa indicating a special proliferative cellular state in those lesions. Oral submucous fibrosis (OSMF) is considered to be a premalignant condition with potential to get transformed into oral squamous cell carcinoma (OSCC). The present study was done to assess the PCNA expression in different grades and in different layers of epithelium of OSMF and to compare the expression of PCNA in OSMF with OSCC.

Materials and Methods: A group of 40 histopathologically diagnosed, formalin fixed, paraffin embedded tissue samples were included in study. The study group was further divided into 2 groups; 30 OSMF and 10 OSCC. These samples were collected from Department of Oral and Maxillofacial Pathology, Government Dental College and Research Institute, Bangalore.

The samples were subjected to immunohistochemical method using indirect immunoenzyme LSAB method.

Results: All 40 cases showed positivity for PCNA. The percentage of positive cells was more in basal and suprabasal layer both in OSMF and OSCC, whereas the greater percentage of positive cells was seen in the superficial layer of OSCC. All OSMF cases showed positive expression in basal and suprabasal layer and only 77% of cases showed positive PCNA expression in the superficial layer with variable immunoreactivity and 23% did not show any positive staining in the superficial layer. The percentage of positive cells and the intensity of staining increased as the disease severity increased in OSMF.

Conclusion: Increased proportion of cells expressed PCNA staining which are in proliferative layers of OSMF. This biomarker provides an insight into the biological behaviour of the condition that substantiates its potentially malignant nature and may also provide an intermediate end point in chemotherapeutic trials.

Keywords: Biomarker, Malignant potential, Oral squamous cell carcinoma, Proliferative pool

INTRODUCTION

Oral submucous fibrosis (OSMF) is a chronic debilitating disease of the oral cavity affecting an estimated 2.5 million people mostly in the Indian subcontinent [1-3]. OSMF is characterized by inflammation and progressive fibrosis of the submucosal tissues (lamina propria and deeper connective tissues) resulting in difficulties in mouth-opening, tongue movement, intolerance to spicy food and rigidity of the lip [4]. The buccal mucosa is the most commonly involved site, but any part of the oral cavity can be involved, even the pharynx and oesophagus [5,6]. Histopathologically graded as Grade I: loose, thin and thick fibers, Grade II: loose or thick fibers with partial hyalinization, and Grade III: complete hyalinization [7]. Various factors have been implicated in the development of OSMF including nutritional deficiencies and immunological processes, but the available epidemiological evidence indicates that chewing betel quid (containing Arecanut, tobacco, slaked lime or other spices) is an important risk factor for OSMF [8-11].

The condition is well-recognized for subsequent malignant transformation and is therefore, considered as a potentially malignant condition. It has been stated that atrophic changes in the mucosa predispose to malignant changes in epithelium. The malignant potential in OSMF was first described by Paymaster in 1956 and emphasized subsequently by other authors based on clinical and epidemiological grounds. A malignant transformation rate between 3% and 7.6% has been reported followed for a period of 17 y. Precancerous nature of OSMF is further substantiated by the observation of co-existent oral-leukoplakia and concomitant finding of oral-carcinoma [12-17].

Immunological methods of assessing cell proliferation have the advantage of simultaneous analysis of histopathology and cell proliferation features. A number of immunohistochemical and nucleic acid markers of cell proliferation are now available. One that

has been well-characterized is the Proliferating cell nuclear antigen (PCNA), which is the auxiliary protein of DNA polymerase- δ that is concentrated in the nucleus. PCNA plays an important role in DNA synthesis, DNA repair, cell cycle progression and cell proliferation. In both cell culture system and fresh tissue specimens, PCNA levels are very low and undetectable in quiescent cells, but the production of this protein occurs prior to DNA replication. This protein increases at G1 and S phase and decreases at G2 phase of the cell cycle and hence, it is a more sensitive index of proliferation [18,19]. Increase in PCNA expression has been observed as tissues progressed from normal epithelium to hyperplasia and dysplasia and premalignant and malignant lesions of oral cavity [20-24].

The present study attempts to evaluate staining pattern of PCNA in different layers and different grades of epithelium in OSMF and to compare the staining between OSMF and OSCC to substantiate the precancerous nature of OSMF.

MATERIALS AND METHODS

All specimens were retrieved (Jan 2008 to May 2009) from archival paraffin blocks in the Department of Oral pathology, Government Dental College and research institute, Bangalore, India. A total of 30 cases of OSMF and 10 cases of OSCC were selected and studied for the expression of PCNA. Among 30 cases of OSMF; 1 case was grade I, 7 cases were grade II and rest 22 cases were grade III [7].

Biogenex Lsab+ system peroxidase (Biogenex laboratories, CA, USA) kit was used. Contents : Hydrogen peroxidase (3% H₂O₂ in water); Link secondary antibody (Biotinylated anti-rabbit, anti-mouse and anti-goat immunoglobulin in phosphate buffered saline containing carrier protein on 15mM azide); Streptavidin peroxidase (Streptavidin conjugated horse radish peroxidase in phosphate buffered saline containing carrier protein and antimicrobial agent); Buffered substrate (Buffered substrate solution, pH 7.2, containing

hydrogen peroxide and a preservative); DAB chromogen (3,3-diamino benzidine chromogen solution) [25]. Anti PCNA (prediluted, BIOGENEX Corporation, CA, USA); Phosphate buffered saline (PBS); Xylene; Absolute alcohol; 95% alcohol; Distilled water; Mayers Haematoxylin; 1% acid alcohol; Mounting medium (DPX). The following reagents were prepared prior to staining. Phosphate buffered saline (PBS) (Wash solution, buffer bath) 0.05 M/L, 0.1 mol /L NaCl (pH 7.2-7.6). Citrate buffer: 10m mol/L citrate (pH 6.0). Substrate chromogen solution (4-7 sections): Transfer 1ml aliquot of buffered substrate into the calibrated test tube. To this add one drop (approximately 20 µl) of DAB chromogen. The solution was mixed and applied to tissue sections with the provided Pasteur pipette.

Procedure: Serial sections of 5µm thickness were taken on silanised slides for immunohistochemistry. The slides were deparaffinized by heating on the slide warmer at 60°C for 10-20 min. The slides were subsequently rehydrated by keeping in three baths each of xylene, absolute alcohol and 95% alcohol for 5, 3 and 3 min respectively. Then, the slides were immersed in distilled water for 30 sec. Antigen retrieval was done using heat induced epitopes retrieval (HIER) microwave oven method. Slides were placed in plastic jar containing 10 mM citrate buffer (pH 6.0) and heated for 20 min. They were then allowed to cool for 20 min and taken out and washed with wash buffer. All reagents were equilibrated to room temperature (20°-25°C) prior to immunostaining. All the incubations were carried out at room temperature, with a humidifying chamber. At no time, the tissue sections were permitted to dry during the staining procedure: Step 1: Peroxidase block: After tapping off excess buffer, the specimens were covered with 3% hydrogen peroxide for 15 min. Then the slides were gently washed with distilled water and placed in a buffer bath for 5min. Step 2: Primary antibody application: Excess buffer was tapped off, and primary antibody was used to cover the specimen. For negative control, PBS was used instead of the primary antibody. The slides were incubated for one hour at room temperature in a humidifying chamber. Then the slides were rinsed in distilled water and placed in fresh buffer bath. Step 3: Link (Secondary antibody) application: Excess buffer was tapped off, and the slides were incubated for 15 min with link and then rinsed gently with distilled water, and then placed in buffer bath for 30 min. Step 4: Streptavidin peroxidase application: Excess buffer was tapped off as before, and the specimens were incubated with streptavidin peroxidase for 30 min. The slides were washed gently with distilled water and placed in buffer bath for 5minutes. Step 5: Substrate chromogen application: Excess buffer was tapped off and the sections were covered with substrate chromogen for 2 to 10 min. Then the slides were gently rinsed with distilled water. Step 6: Mayers haematoxylin counter staining: The slides lightly stained with Mayers haematoxylin, washed gently under running water for 10 minutes. They were dehydrated and dipped in xylene and mounted in DPX, a non-aqueous permanent mounting medium using converslips.

Interpretation of staining: Presence of brown colored end product at the site of target antigen was indicative of positive reactivity. The negative control tissue demonstrated absence of specific staining. To analyse more thoroughly the expression of PCNA, the oral epithelium was divided into 3 layers, basal layer, suprabasal layer and superficial layer excluding the surface keratinized layer.

The percentage of positive cells was calculated by counting the number of cells per 1 mm² field. It was then categorized as: More than 50% of positive cells were scored as (+++); 25%-50% of positive cells were scored as (++); 10%-25% of positive cells were scored as (+) and fewer than 10% of positive cells were scored as (±).

STATISTICAL ANALYSIS

The Statistical software SPSS 15.0, Stata 8.0, MedCalc 9.0.1 and Systat 11.0 were used for the analysis of the data. Descriptive statistical analysis has been carried out in the present study. Results

on continuous measurements are presented on Mean ± SD (Min-Max) and results on categorical measurements are presented in Number (%). Significance is assessed at 5 % level of significance. Fisher Exact test has been used to find the significance of PCNA expression between different grades of OSMF and Chi-square was used for comparison of PCNA expression in OSMF and OSCC.

RESULTS

All specimens of OSMF and OSCC showed positive staining for PCNA. Staining was observed in oral epithelium and in infiltrating inflammatory cells. Staining for PCNA was localized to the nucleus and exhibited a differential pattern of expression in OSMF.

Comparison of PCNA expression between different grades of OSMF:

There was no statistical significant mean difference of PCNA expression in different grades of OSMF but, the greater percentage of positive cells was seen more in grade III than in the grade II cases. All OSMF cases showed positive expression in basal and suprabasal layers and only 77% of cases showed positive PCNA expression in the superficial layer [Table/Fig-1-3].

PCNA expression	Total	Grade I	Grade II	Grade III	p-value
Nil	0	0	0	0	-
+	2	0	1(50.0%)	1(50.0%)	0.469(NS)
++	14	1(7.1%)	4(28.6%)	9(64.3%)	0.519(NS)
+++	14	0	2(14.3%)	12(85.7%)	0.297(NS)
Total	30	1(3.3%)	7(23.3%)	22(73.3%)	-

[Table/Fig-1]: Expression of PCNA in different grades of OSMF in Basal layer Where, +++ (or 3+) represents more than 50% positive cells; ++ (or 2+) represents 25%-50%; + (or 1+) represents 5%-25%; and, +/- represents less than 5%. OSMF - Oral submucous fibrosis. (NS: Not Significant)

PCNA expression	Total	Grade I	Grade II	Grade III	p-value
Nil					-
+	7	0	1(14.3%)	6(85.7%)	0.728(NS)
++	19	1(5.3%)	5(26.3%)	13(68.4%)	0.795(NS)
+++	4	0	1(25.0%)	3(75.0%)	1.000(NS)
Total	30	1(3.3%)	7(23.3%)	22(73.3%)	-

[Table/Fig-2]: Expression of PCNA in different grades of OSMF in Suprabasal layer Where, +++ (or 3+) represents more than 50% positive cells; ++ (or 2+) represents 25%-50%; + (or 1+) represents 5%-25%; and, +/- represents less than 5%. OSMF - Oral submucous fibrosis. (NS: Not Significant)

PCNA expression	Total	Grade I	Grade II	Grade III	p-value
Nil	7	0	1 (14.3%)	6(85.7%)	-
+	15	1(6.7%)	5(33.3%)	9(60.0%)	0.215(NS)
++	3	0	0	3(100.0%)	1.000(NS)
+++	5	0	1(20.0%)	4(80.0%)	1.000(NS)
Total	30	1(3.3%)	7(23.3%)	22(73.3%)	-

[Table/Fig-3]: Expression of PCNA in different grades of OSMF in superficial layer Where, +++ (or 3+) represents more than 50% positive cells; ++ (or 2+) represents 25%-50%; + (or 1+) represents 5%-25%; and, +/- represents less than 5%. OSMF - Oral submucous fibrosis. (NS: Not Significant)

PCNA expression	OSMF	OSCC	p-value
Nil	0	0	-
+	2(6.7%)	0	1.000(NS)
++	14(46.7%)	1(10.0%)	0.060(NS)
+++	14(46.7%)	9(90.0%)	0.082(NS)
Total	30(100.0%)	10(100.0%)	-

[Table/Fig-4]: Comparison of PCNA expression in OSMF and OSCC in Basal layer Where, +++ (or 3+) represents more than 50% positive cells; ++ (or 2+) represents 25%-50%; + (or 1+) represents 5%-25%; and, +/- represents less than 5%. OSMF - Oral submucous fibrosis; OSCC - Oral squamous cell carcinoma. (NS: Not Significant)

PCNA expression	OSMF	OSCC	p-value
Nil	0	0	-
+	7(23.3%)	0	0.161(NS)
++	19(63.3%)	6(60.0%)	1.000(NS)
+++	4(13.3%)	4(40.0%)	0.338(NS)
Total	30(100.0%)	10(100.0%)	-

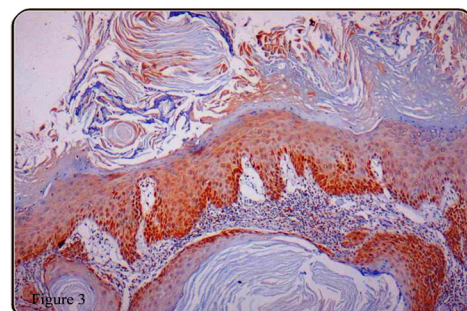
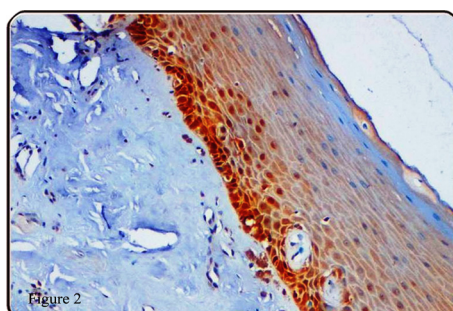
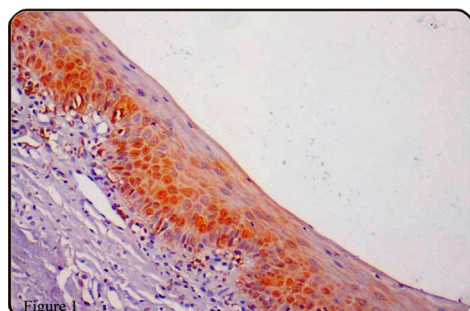
[Table/Fig-5]: Comparison of PCNA expression in OSMF and OSCC in Suprabasal layer

Where, +++ (or 3+) represents more than 50% positive cells; ++ (or 2+) represents 25%-50%; + (or 1+) represents 5%-25%; and, +/- represents less than 5%. OSMF - Oral submucous fibrosis; OSCC - Oral squamous cell carcinoma. (NS: Not Significant)

PCNA expression	OSMF	OSCC	p-value
Nil	7(23.3%)	0	-
+	15(50.0%)	0	0.006(S)
++	3(10.0%)	4(40.0%)	0.052(NS)
+++	5(16.7%)	6(60.0%)	0.196(NS)
Total	30(100.0%)	10(100.0%)	-

[Table/Fig-6]: Comparison of PCNA expression in OSMF and OSCC in Superficial layer

Where, +++ (or 3+) represents more than 50% positive cells; ++ (or 2+) represents 25%-50%; + (or 1+) represents 5%-25%; and, +/- represents less than 5%. OSMF - Oral submucous fibrosis; OSCC - Oral squamous cell carcinoma. (NS: Not Significant, S: Significant)



[Table/Fig-7]: PCNA staining seen in grade II OSMF; showing basal and supra basal staining pattern **[Table/Fig-8]:** The specimen shows PCNA positive nuclear staining in nearly all basal, suprabasal and part of superficial layer in grade III OSMF **[Table/Fig-9]:** The specimen shows positive PCNA stained cells in nearly all layers of the epithelium in OSCC

Comparison of PCNA expression between OSMF and OSCC:

There was no statistical significant mean difference of PCNA expression in basal and suprabasal layers between OSCC and OSMF. But there was a statistical significant mean difference in PCNA expression in superficial layers. The percentage of positive cells was more in basal and suprabasal layer both in OSMF and OSCC, whereas the greater percentage of positive cells was seen in the superficial layer of OSCC [Table/Fig-4-9].

DISCUSSION

In the present study, among the 30 cases of OSMF, all showed positivity for PCNA with variable immunoreactivity in different layers of epithelium and in different grades of OSMF. Among 30 OSMF patients high intensity staining in basal layer was seen in 12 grade III and 2 grade II cases. This observation suggests that intensity of staining in basal cells of OSMF vary from moderate to high and the percentage of cells exhibiting high intensity staining is directly related to grade of OSMF. In OSCC 9 (90%) cases showed high intensity staining and 1 (10%) cases showed moderate intensity staining. This suggests Basal layer in both OSMF and OSCC having significant proliferative activity.

Out of 4 cases of OSMF which showed high intensity staining in supra basal layer; 3 were of grade III and 1 was grade II. In OSCC 6 (60%) cases showed moderate intensity and 4 (40%) cases showed high intensity staining none of them showed mild intensity of staining. It is seen that staining in suprabasal layers of OSMF vary from mild to moderate to high intensity and in OSCC it varied from moderate to high intensity of staining. These findings suggest an increased proliferative activity even in the suprabasal layer of OSMF indicating the aggressiveness of the condition. A significant basal and suprabasal pattern of staining was seen in cases of OSMF correlating with previous study done by Srinivasan and Jewel [19]. This finding suggests that major proportion of cells that exhibit PCNA are in the proliferative pool of OSMF.

Superficial layer of 5 cases of OSMF showed high intensity staining of which 4 were of grade III and 1 was of grade II. However; among 10 cases of OSCC 6 (60%) showed high intensity and 4 (40%) cases showed moderate intensity staining. A mild to high intensity staining

was seen in OSMF, whereas in OSCC all the cases showed strong positivity to PCNA showing moderate to high intensity of staining. This finding suggests that even though not all cases exhibited positive PCNA expression in OSMF a significant portion of cells in superficial layer of OSMF also shows proliferative activity that leads to progression of the condition towards malignancy.

Huang et al., [20] found that among premalignant lesions; 90.8% of cases showed suprabasal staining with the progression of lesion toward malignancy. There was significant predilection for basal and suprabasal staining pattern for PCNA as compared with strictly basal staining seen in normal and benign epithelial conditions. Suprabasal positive reactivity was demonstrated in 40% of the benign, reactive hyperplasias, 56.25% of specimens with atypia, 61.64% of dysplasias and 64% of all carcinomas in situ. All cases that exhibited even a small area consistent as carcinoma in situ were histologically diagnosed as carcinomas in situ.

Martinez et al., [24] analysed PCNA expression in 10 samples of normal mucosa, 23 benign oral lesions (18 hyperplasia and 5 oral lichen planus), 10 oral lesions with epithelial dysplasia, and 10 dysplastic epithelia adjacent to tumors. Immunocytochemical stained sections were scored for the presence or absence of suprabasal PCNA positivity regardless of location. As indicated by results, PCNA expression in suprabasal layers increased with degree of epithelia dysplasia and histological dysplastic epithelium sample adjacent to tumors. The percentage of suprabasal PCNA was insignificant in normal oral mucosa samples and benign oral lesions samples. The present study suggests that there is increased proliferative activity in basal layer and suprabasal layer in grade II and grade III of OSMF and too little extent in the superficial layer. Atrophy of the epithelium in OSMF can be attributed to the increased loss of cells from the surface despite increased proliferative activity seen it indicates that aggressiveness of the condition increases as the disease severity increases and correlates with reported biologic behavior of the condition.

LIMITATIONS OF THE STUDY

The sample size used in this study was small to form a hypothesis; however it can be used as a base to conduct further studies using larger sample size.

CONCLUSION

There was a significant predilection for basal/suprabasal staining pattern for proliferating cell nuclear antigen in OSMF. PCNA expression increased in basal, supra basal and superficial layers of OSMF as the severity of the condition increased. Cell cycle analysis using PCNA immunohistochemistry can be the basis for response to various treatment regimens of OSMF.

REFERENCES

- [1] Cox SC, Walker DM. Oral submucous fibrosis. A review. *Aust Dent J*. 1996;41(5):294-99.
- [2] Pindborg J, Chawla TN, Misra RK, Nagpaul RK, Gupta YK. Frequency of oral carcinoma, leukoplakia, leukokeratosis, leukoedema, submucous fibrosis and lichen planus in 10,000 Indians in Lucknow, Uttar Pradesh, India. Preliminary report. *J Dent Res*. 1965;44:615.
- [3] Pindborg JJ, Mehta FS, Gupta PC, Daftary DK. Prevalence of oral submucous fibrosis among 50,915 Indian villagers. *Br J Cancer*. 1960;22:646-54.
- [4] Pindborg JJ, Chawla TN, Srivastava AN, Gupta D, Mehrotra ML. Clinical aspects of Oral Submucous Fibrosis. *Acta Odont scand*. 1964;22:679-91.
- [5] Haider SM, Merchant AT, Fikree FF, Rahbar MH. Clinical and functional staging of oral submucous fibrosis. *Br J of Oral and Maxillofac Surg*. 2000;38:12-15.
- [6] Pindborg JJ. Oral submucous fibrosis. *Oral Surg Med Oral Pathol Oral Radiol Endod*. 1996;22:764-69.
- [7] Kiran KK, Saraswathi TR, Ranganathan K, Umadevi M, Elizabeth E. Oral submucous fibrosis: A clinico-histopathological study in Chennai. *Indian J Dent Res*. 2007;18(3):106-11.
- [8] Pindborg JJ. Oral submucous fibrosis: a review. *Annals of the Academy of Medicine, Singapore*. 1989;18:603-07.
- [9] Pillai R, Balaram P, Reddiar KS. Pathogenesis of oral submucous fibrosis: relationship to risk factors associated with oral cancer. *Cancer*. 1962;69:2011-20.
- [10] Tilakaratne WM, Kliniowski MF, Saku T, Peters TJ, Warnakulasuriya S. Oral submucous fibrosis: Review on aetiology and pathogenesis. *Oral Oncol*. 2006;42:561-68.
- [11] Sinor PN, Gupta PC, Murti PR. A case-control study of oral submucous fibrosis with special reference to the etiologic role of areca nut. *Oral Pathol Med*. 1990;19:94-98.
- [12] Paymaster JC. Cancer of buccal mucosa: a clinical study of 650 cases in Indian patients. *Cancer*. 1956;9:431-35.
- [13] Pindborg JJ, Murti PS, Bhonsle RB, Gupta PC, Daftary DK, Mehta FS. Oral submucous fibrosis as a precancerous condition. *Scandinavian J of Dent Res*. 1984;92(3):224-29.
- [14] Murti PR, Bhonsle RB, Pindborg JJ, Daftary DK, Gupta PC, Mehta FS. Malignant transformation rate in oral submucous fibrosis over a 17-year period. *Community Dent Oral Epidemiol*. 1985;13:340-41.
- [15] Pindborg JJ, Mehta FS, Daftary DK. Occurrence of epithelial atypia in 51 Indian villagers with oral submucous fibrosis. *Br J Cancer*. 1970;24:253-57.
- [16] Gupta PC, Bhonsle RB, Murti PR, Daftary DK, Mehta FS, Pindborg JJ. An epidemiologic assessment of cancer risk in oral precancerous lesions in India with special reference to nodular leukoplakia. *Cancer*. 1989;63:2247-52.
- [17] Kurki P, Vanderlaan M, Dolbear F, Grey J, Tan EM. Expression of proliferating cell nuclear antigen (PCNA/cyclin) during the cell cycle. *Exp Cell Res*. 1986;166:209-19.
- [18] Chiang CP, Lang MJ, Liu BY, Wang, Leu JS, Hahn LJ, Kuo MYP. Expression of proliferating cell nuclear antigen (PCNA) in oral submucous fibrosis, oral epithelial hyperkeratosis and oral epithelial dysplasia in Taiwan. *Oral Oncol*. 2000;36(4):353-59.
- [19] Srinivasan M, Jewell SD. Quantitative estimation of PCNA, c-myc, EGFR and TGF- α in oral submucous fibrosis- an immunohistochemical study. *Oral Oncol*. 2001;37:461-67.
- [20] Huang WY, Coltrera M, Schubert M, Morton T, Truelove E, Wash S. Histological evaluation of proliferating cell nuclear antigen (PC 10) in oral epithelial hyperplasia and premalignant lesions. *Oral Surg Med Oral Pathol Oral Radiol Endod*. 1994;78:748-54.
- [21] Tsai ST, Jin YT. Proliferating cell nuclear antigen (PCNA) expression in oral squamous cell carcinomas. *J Oral Pathol Med*. 1995;24(7):313-15.
- [22] Tsuji T, Sasaki K, Kimura Y, Yamada K, Mori M, Shinozaki F. Measurement of proliferating cell nuclear antigen (PCNA) and its clinical application in oral cancers. *Int J Oral Maxillofac Surg*. 1992;21(6):369-72.
- [23] Tsuji T, Shrestha P, Yamada K, Takagi H, Shinozaki F, Sasaki K et al. Proliferating cell nuclear antigen in malignant and pre-malignant lesions of epithelial origin in the oral cavity and the skin: an immunohistochemical study. *Virchows Archiv A Pathol Anat*. 1992;420:377-83.
- [24] Martínez-Lara I, González-Moles MA, Ruiz-Avila I, Bravo M, Ramos MC, Fernández-Martínez JA. Proliferating cell nuclear antigen (PCNA) as a marker of dysplasia in oral mucosa. *Acta Stomatol Belg*. 1996;93(1):29-32.
- [25] Shahela T, et al. Immunohistochemical Expression of PCNA in Epithelial Linings of Selected Odontogenic Lesions. *J Clin Diagn Res*. 2013;7(11):2615-18.

PARTICULARS OF CONTRIBUTORS:

1. Assistant Professor, Department of Oral Pathology, Vydehi institute of dental sciences and research, Bangalore, Karnataka, India.
2. Assistant Professor, Department of Oral Medicine and Radiology, Al-Badar Rural Dental College and Hospital, Gulbarga, Karnataka, India.

NAME, ADDRESS, E-MAIL ID OF THE CORRESPONDING AUTHOR:

Dr. Umashree Narayanappa,
Assistant Professor, Department of Oral Medicine and Radiology, Al-Badar Rural Dental College and Hospital,
Gulbarga, Karnataka-585102, India.
E-mail : dr.umashree@gmail.com

Date of Submission: **Jan 19, 2015**
Date of Peer Review: **Mar 22, 2015**
Date of Acceptance: **Mar 30, 2015**
Date of Publishing: **May 01, 2015**

FINANCIAL OR OTHER COMPETING INTERESTS: None.